

The dynamic study of the pulmonary artery obstruction degree and the right ventricular function in massive pulmonary embolism on CT pulmonary angiography ☆

Jianguo Wang^{a,1,△}, Xiaojuan Guo^{b,1}, Min Liu^{b,1}, Youmin Guo^{b,*}, Chen Wang^{c,*}, Yuanhua Yang^c,
Zhenguo Zhai^c, Li Zhu^{d,1}, Hongxia Ma^d, Yulin Guo^d

^aImaging Center, the Second Affiliated Hospital of Xi'an Jiao Tong University, Xi'an 710004, Shan xi Province, China

^bRadiology Department, Beijing Chaoyang Hospital Affiliated to Capital University of Medical Sciences, Beijing 100020, China

^cRespiratory Medicine, Beijing Chaoyang Hospital Affiliated to Capital University of Medical Sciences, Beijing 100020, China

^dImaging Center, the Affiliated Hospital of Ningxia Medical College, Yinchuan 750004, Ningxia Hui Autonomous Region, China

Received 7 January, 2008

Abstract

Objective: To analyze the value of CTPA in assessing the dissolve of embolus and the function of the right ventricle dynamically. **Methods:** Twenty-three cases of massive pulmonary embolism were analyzed retrospectively. The pulmonary artery obstruction index and the right ventricular function parameters were collected and analyzed on CTPA before thrombolytic therapy, 24 hours and 14 days after therapy, respectively. **Results:** The pulmonary artery obstruction index decreased gradually, and there was significant difference before therapy, 24 hours and 2 weeks after therapy. Twenty-four hours after therapy, the maximal short axes diameter and the maximal transverse area of right ventricle (RV_d , RV_s) decreased significantly, the maximal short axes diameter and the maximal transverse area of left ventricle (LV_d , LV_s) increased significantly, and the RV_d/LV_d , RV_s/LV_s decreased apparently. The pulmonary artery symbolic pressure before and 24 hours after therapy were apparently different. There was no significant difference between azygos vein, the super vena cava, the main pulmonary artery and vein reflux before and after therapy. **Conclusion:** CTPA can evaluate the pulmonary artery obstruction degree and right ventricular function dynamically.

Key words: Pulmonary embolism; Tomography, X-ray computed; Angiography

INTRODUCTION

If untreated, pulmonary embolism is fatal in up to 30% of patients, but the mortality can be reduced to 2%~10% if pulmonary embolism is diagnosed and treated promptly^[1,2]. Death is usually caused by circulatory collapse from acute right heart failure. Pulmo-

nary embolism, especially massive pulmonary embolism, causes abrupt pulmonary arterial hypertension and right ventricular dysfunction, which may progress to right heart failure causing right ventricular infarction, circulatory collapse, and possibly death. This suggests that right ventricular dysfunction should be diagnosed rapidly because these patients may benefit from more aggressive therapies such as thrombolysis or embolectomy in addition to anticoagulation^[3]. Rapid risk stratification is crucial in guiding patient management and identifying patients at higher risk for cardiopulmonary collapse.

In recent years, CT pulmonary angiography (CTPA) has been accepted as the first-line diagnostic modality

☆ This work was supported by National "Eleventh-five" Scientific Item (2006BAI01A06); Shen-zhen City Luohu District Foundation (2007029)

*Corresponding author

E-mail address: cjr_guoyoumin@vip.163.com; cyh-birm@263.net

¹These authors contributed equally to this research work

[△] The author is working at the People's Hospital of Luohu District, Shenzhen 518001, Guangdong Province, China.

in patients suspected of pulmonary embolism^[4]. CTPA can not only diagnose pulmonary embolism with high sensitivity and specificity, but also analyze the right ventricular function by evaluate the right ventricular morphology^[5,6]. There were few studies which accentuated at the evaluation of therapeutic results by CTPA. In this study, twenty-three cases of massive pulmonary embolism had CTPA performed before therapy. 24 hours and 2 weeks post-thrombolytic therapy results were retrospectively reviewed. The right ventricular function parameters at different time reflected on CTPA images were analyzed and compared to determine the value of CTPA in evaluating the improvement of pulmonary artery obstruction degree and right ventricular function after therapy.

MATERIALS AND METHODS

Study samples

Twenty-three CTPA-confirmed pulmonary embolism cases (male 11, female 12, 25-62 years old, average age 48 years) in Beijing Chaoyang Hospital between July 2002 and December 2004 were retrospectively analyzed. All cases manifested as having shock or hypotension, and were defined as having a massive pulmonary embolism^[7]. All cases received systemic thrombolysis immediately after the diagnosis was determined. Before therapy, 24 hours and 2 weeks after therapy, CT pulmonary angiography was performed respectively using the same technology. This study was retrospective and was approved by the institute ethics committee. Since no personal information was revealed, no informed consent was obtained.

CT pulmonary angiography

Spiral CTPA was performed using a GE Highspeed spiral CT scanner (General Electron, dual-row detector) during intravenous administration of 80-100 ml of Omnipaque at 3.5-4 ml/s. Imaging was performed after 12-15 s delay using 2-mm collimation and 0.7 s gantry rotation time. Subsequently, 1 mm reconstruction was performed and used for the final interpretation, which was done on the workstation.

On CTPA, the pulmonary artery obstruction degree and the right ventricular function parameters were analyzed.

The pulmonary artery obstruction degree, expressed as the CT pulmonary artery obstruction index (PAOI), was referenced to the methods proposed by Qanadli *et al*^[8] and Mastora *et al*^[9]. So the presence and location of arterial clots and the degree of arterial obstruction were scored. For comparison, each score was expressed as the percentage of the pulmonary artery that was obstructed. Percentages were calculated by dividing the value obtained with each system by the maximum pos-

sible value for that particular system and then multiplying by 100.

The right ventricular function parameters included the maximal short axes and transverse areas of both ventricles and their ratios respectively, the diameters of the main pulmonary artery (MPA), azygos vein (AZ), and superior vena cava (SVC). The observations of reflux of contrast medium into the inferior vena cava (IVC) and azygos vein were recorded. All parameters were acquired on a single transverse scan. The pulmonary artery systolic pressure (PASP) measured on echocardiography was also recorded.

The maximal short axes diameters (RV_d , LV_d) were measured perpendicular to the long axis of the heart and were defined as the largest distance between the inner aspect of the interventricular septum and the free wall of the ventricle. The maximal transverse areas (RV_s , LV_s) were measured on the image that the ventricles showed the maximal area. The RV_d/LV_d ratio and the RV_s/LV_s was then calculated from these measurements.

The diameter of the main pulmonary artery was measured proximal to its branching division. Measurements were taken of the portion of the azygos vein facing the right tracheal wall, and of the superior vena cava at the level of the azygos arch.

Statistical analysis

A *P* value less than 0.05 was considered statistically significant. Statistical analysis was performed with a statistical software system SPSS 13.0. CT pulmonary artery obstruction index and the right ventricular function parameters were analyzed using the one-way ANOVA, nonparametric test, and Chi-Square test respectively according to the data.

RESULTS

The CT pulmonary artery obstruction index and the right ventricular function parameters were listed in Tab 1.

The CT pulmonary artery obstruction index (Qanadli *et al* and Mastora *et al*) decreased apparently after therapy, and there was significant difference before therapy, 24 hours and 2 weeks after therapy ($P < 0.001$).

Twenty-four hours after therapy, compared with the data before therapy, the maximal short axes diameter and transverse area of right ventricle decreased ($P < 0.001$), the maximal short axes diameter and transverse area of left ventricle increased ($P < 0.001$), the RV_d/LV_d and RV_s/LV_s decreased ($P < 0.001$), and the pulmonary artery systolic pressure decreased ($P = 0.005$). Two weeks of after therapy, the above data remained stable and there was no significant difference compared with those before therapy and 24 hours after therapy ($P > 0.05$) (Fig 1).

There was no significant difference of the diameter

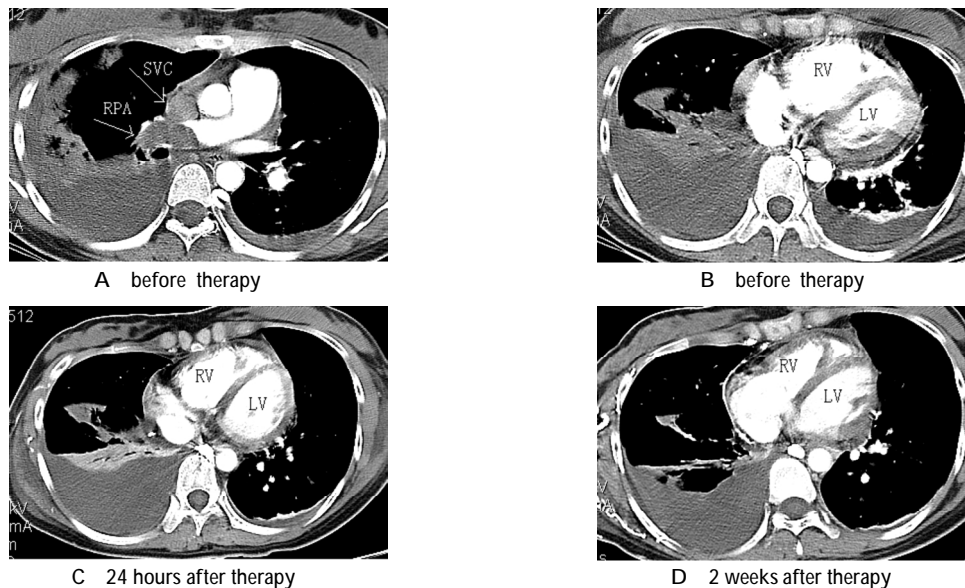
of azygos vein, the superior vena cava, the main pulmonary artery, and the reflux into the azygos vein and

the inferior vena cava between the data of before therapy, 24 hours after therapy and 2 weeks after therapy ($P > 0.05$).

Tab 1 CTPA pulmonary artery obstruction index and right ventricular function parameters

Parameters	Before therapy	24 hours after therapy	2 weeks after therapy
CT pulmonary artery obstruction index			
Qanadli*	48.42 ± 4.18(50)	39.22 ± 13.19(42.5)	26.67 ± 19.45(25)
Mastora*	47.88 ± 6.38(46.45)	23.55 ± 12.10(25.17)	12.98 ± 11.42(8.39)
Right ventricular function parameters			
RV _d (cm)*	5.07 ± 0.78	4.58 ± 0.80	4.48 ± 0.77
LV _d (cm)*	3.57 ± 0.66	4.41 ± 0.47	4.53 ± 0.58
RV _d /LV _d *	1.59 ± 0.43(1.49)	1.07 ± 0.28(0.99)	1.14 ± 0.44(0.98)
RV _s (cm ²)*	25.42 ± 5.99	23.10 ± 5.86	22.91 ± 4.94
LV _s (cm ²)*	20.17 ± 4.84	26.37 ± 5.11	28.46 ± 5.77
RV _s /LV _s *	1.38 ± 0.31(1.41)	0.94 ± 0.19(0.98)	0.98 ± 0.36(0.99)
MPA(cm)*	3.20 ± 0.48	3.06 ± 0.48	2.92 ± 0.46
AZ(cm)*	1.43 ± 0.25	1.36 ± 0.19	1.40 ± 0.27
SVC(cm)*	2.08 ± 0.36	2.04 ± 0.38	1.99 ± 0.34
PASP(mmHg)*	58.61 ± 19.04	40.92 ± 18.19	37.22 ± 12.39
Reflux into AZ [△]	10	5	7
Reflux into IVC [△]	8	4	3

*:Data are the $\bar{x} \pm s$. The data in the bracket are the median. [△]:Data are the number of cases.



A and B showed the right pulmonary artery embolism(RPA), the embolus in the superior vena cava(SVC), the enlarged right ventricle(RV), and the shrunk left ventricle(LV). C and D showed after therapy, the RV decreased and the LV increased.

Fig 1 The result of CT pulmonary angiography in one patient

DISCUSSION

Acute massive pulmonary embolism is a life-threatening condition with considerable mortality. When pulmonary embolism is fatal, patients usually die after right ventricular failure and circulatory collapse, which frequently occurs within the first hours after admission^[1,10]. Patients with right heart dysfunction have a higher mortality rate than those without right ventricular dysfunction, even if they are hemodynamically stable at presentation^[11]. So it is very important to evaluate the

right ventricular function of pulmonary embolism cases, especially massive pulmonary embolism.

In recent years, computed tomography(CT) has emerged as a first-line test for patients with suspected pulmonary embolism in many institutions. Computed tomography not only allows direct visualization of emboli but gives information regarding the severity degree of the obstructing pulmonary vasculature^[9] and the status of the right ventricle^[8,12].

In massive pulmonary embolism, the increasing

pulmonary arterial pressure and the right ventricular afterload cause right ventricular dysfunction. In the event of a sudden increase of afterload, right ventricular wall tension becomes elevated, followed by dilatation and hypokinesia of the right ventricle and secondary tricuspid regurgitation. The interventricular septum may shift toward the left ventricle because of the restraints of the pericardium. This shift causes decreased left ventricular filling and cardiac output, which may lead to a vicious cycle of falling systemic pressure, ventricular ischemia, and further dilatation of the right ventricle. The above signs of right ventricular dysfunction are readily visible on CTPA. Thus, CT has the potential to serve as a diagnostic and prognostic study.

In our study, we analyzed the pulmonary artery obstruction degree and the right ventricular function on CTPA, the latter including the diameter and area of both ventricles, and the changes of upstreaming veins. We used the same methods as previous investigators^[5,13-15]. These methods were simple, reproducible, and reliable for the qualitatively assessment of the patient's condition.

There were 23 cases of massive pulmonary embolism in this study, and all manifested hypotension or shock. Our results indicated that before therapy, the CT pulmonary artery obstruction index reached around 48%, the RV_d/LV_d and RV_s/LV_s reached around 1.5 and 1.4 (the normal value was <1.0), and the pulmonary symbolic pressure reached around 58mmHg, all of which indicated the damage of the right ventricular function. Twenty-four hours after immediate thrombolytic therapy, the CT pulmonary artery obstruction index decreased ($P < 0.001$), the right ventricle diminished and the left ventricle enlarged ($P < 0.001$), the pulmonary artery symbolic pressure decreased ($P = 0.005$), which indicated the dissolve of embolus and the prompt improvement of the right ventricular function. Two weeks after therapy, although the CT pulmonary artery obstruction index decreased continuously ($P < 0.001$), the right ventricular function kept relatively stable ($P > 0.05$). Our results suggested that the immediate thrombolytic therapy was very important for the improvement of the patient's condition, and the following therapy was helpful in maintaining the stabilization of the therapeutic results. So for every patient, as soon as the diagnosis of massive pulmonary embolism was made, thrombolytic therapy should be performed immediately.

We found no significant difference in the diameter of azygos vein, the superior vena cava, the main pulmonary artery, and the influx into the azygos vein and the inferior vena cava between the data of before therapy, 24 hours and 2 week after therapy ($P > 0.05$), which was

maybe due to the prompt dissolve of embolus and recovery of right ventricular function before the above parameters were affected by the obstruction of the pulmonary artery.

Some studies have shown promising results in correlating CT signs with clinical outcomes. Van der Meer *et al*^[5] demonstrated an increased mortality rate among those who have a right-to-left ventricular ratio >1 and a pulmonary artery obstruction index of $>40\%$. Several studies have shown that right ventricle enlargement on CT predicted subsequent admission to the intensive care unit^[16], adverse clinical events^[17], and early death^[18]. Collomb *et al*^[13] found that the CT pulmonary artery obstruction index can be used as an indicator of the hemodynamic severity of PE, reflected by a mean score of 54% in patients with severe PE and 24% in patients with nonsevere PE. Ghaye *et al*^[6] reported that, RV_d , LV_d , RV_d/LV_d ratio, azygos vein, superior vena cava, and aorta diameters; and contrast medium reflux into the inferior vena cava were significantly different between survivors and nonsurvivors ($P < 0.05$), and RV_d/LV_d ratio and azygos vein diameter allowed correct prediction of survival in 89% of pulmonary embolism patients ($P < 0.001$). The previous data showed that CTPA should not only be used as the diagnostic modality, but also as a tool to assess the prognosis and therapeutic strategy.

Our results indicate that series CTPA examinations can directly show the dissolve of the embolus and the function improvement of right ventricle. CTPA should be performed after therapy as the regularity for the assessment of the therapy effect.

References

- [1] Moser KM. Venous thromboembolism. *Am Rev Respir Dis* 1990; 141:235-49.
- [2] Goldhaber SZ, Visani L, De Rosa M. Acute pulmonary embolism: clinical outcomes in the International Cooperative Pulmonary Embolism Registry (ICOPER). *Lancet* 1999;353:1386-9.
- [3] Goldhaber SZ, Elliott CG. Acute pulmonary embolism, II: risk stratification, treatment, and prevention. *Circulation* 2003;108:2834-8.
- [4] Schoepf UJ, Costello P. CT angiography for diagnosis of pulmonary embolism: state of the art. *Radiology* 2004;230: 329-37.
- [5] van der Meer RW, Pattynama PM, van Strijen MJ, van den Berg-Huijsmans AA, Hartmann IJ, Putter H, *et al*. Right ventricular dysfunction and pulmonary obstruction index at helical CT: prediction of clinical outcome during 3-month follow-up in patients with acute pulmonary embolism. *Radiology* 2005;235:798-803.
- [6] Ghaye B, Ghuyssen A, Willems V, Lambermont B, Gerard P, D'Orto V, *et al*. Severe pulmonary embolism: pulmonary artery clot load scores and cardiovascular parameters as predictors of mortality. *Radiology* 2006;239: 884-91.
- [7] Tobicki A, Beek EJR, Charbonnier B. Guidelines on diagnosis and management of acute pulmonary embolism. *Eur Heart J* 2000;21:

- 1301-36.
- [8] Qanadli SD, El Hajjam M, Vieillard-Baron A, Joseph T, Mesurole B, Oliva VL, Barré O, et al. New CT index to quantify arterial obstruction in pulmonary embolism: comparison with angiographic index and echocardiography. *AJR* 2001;176: 1415-20.
- [9] Mastora I, Remy-Jardin M, Masson P, Galland E, Delannoy V, Bauchart JJ, et al. Severity of acute pulmonary embolism: evaluation of a new spiral CT angiographic score in correlation with echocardiographic data. *Eur Radiol* 2003;13:29-35.
- [10] Wood KE. Major pulmonary embolism: review of a pathophysiologic approach to the golden hour of hemodynamically significant pulmonary embolism. *Chest* 2002;121:877-905.
- [11] Grifoni S, Olivetto I, Cecchini P, Pieralli F, Camaiti A, Santoro G, et al. Short-term clinical outcome of patients with acute pulmonary embolism, normal blood pressure, and echocardiographic right ventricular dysfunction. *Circulation* 2000; 101:2817-22.
- [12] Oliver TB, Reid JH, Murchison JT. Interventricular septal shift due to massive pulmonary embolism shown by CT pulmonary angiography: an old sign revisited. *Thorax* 1998;53:1092-4.
- [13] Collomb D, Paramelle PJ, Calaque O, Bosson JL, Vanzetto G, Barnoud D, et al. Severity assessment of acute pulmonary embolism: evaluation using helical CT. *Eur Radiol* 2003;13: 1508-14.
- [14] Contractor S, Maldjian PD, Sharma VK, Gor DM. Role of helical CT in detecting right ventricular dysfunction secondary to acute pulmonary embolism. *J Comput Assist Tomogr* 2002;26:587-91.
- [15] Mansencal N, Joseph T, Vieillard-Baron A, Langlois S, El Hajjam M, Qanadli SD, et al. Diagnosis of right ventricular dysfunction in acute pulmonary embolism using helical computed tomography. *Am J Cardiol* 2005;95:1260-3.
- [16] Araoz PA, Gotway MB, Trowbridge RL, Bailey RA, Auerbach AD, Reddy GP, et al. Helical CT pulmonary angiography predictors of in-hospital morbidity and mortality in patients with acute pulmonary embolism. *J Thorac Imaging* 2003;18:207-16.
- [17] Quiroz R, Kucher N, Schoepf UJ, Kipfmüller F, Solomon SD, Costello P, et al. Right ventricular enlargement on chest computed tomography: prognostic role in acute pulmonary embolism. *Circulation* 2004;109:2401-4.
- [18] Schoepf UJ, Kucher N, Kipfmüller F, Quiroz R, Costello P, Goldhaber SZ, et al. Right ventricular enlargement on chest computed tomography: a predictor of early death in acute pulmonary embolism. *Circulation* 2004;110:3276-80.

